

Method for Optimizing Topography-guided Ablation of Highly Aberrated Eyes With the ALLEGRETTO WAVE Excimer Laser

David T.C. Lin, MD, FRCSC; Simon P. Holland, MD, FRCSC; Karolinne Maia Rocha, MD, PhD; Ronald R. Krueger, MD, MSE

ABSTRACT

PURPOSE: To evaluate the clinical outcomes of custom topographic neutralizing technique in treating highly aberrated eyes using the WaveLight ALLEGRETTO WAVE Excimer Laser.

METHODS: A retrospective consecutive case series of 67 eyes with decentered ablations and 48 eyes with symptomatic small optical zones after previous LASIK underwent topography-guided retreatment with the ALLEGRETTO WAVE. Sixteen keratoconus eyes underwent topographic neutralizing technique photorefractive keratectomy (PRK). The study assessed preoperative and 6-month and 1-year postoperative results regarding best spectacle-corrected visual acuity (BSCVA), uncorrected visual acuity (UCVA), topography, and predictability.

RESULTS: Sixty-seven eyes with previously decentered optical zones had an improvement of centration from 0.92 mm preoperatively to 0.30 mm postoperatively relative to pupil center ($P < .01$). Twenty-nine percent of these eyes gained 1 or more lines of BSCVA, whereas 71% had no change in BSCVA. Forty-eight eyes with previously small optical zones had an increase of the central moniodiopic optical zone from 3.9 mm to 5.6 mm ($P < .01$). Nineteen percent of eyes had an improvement of at least 1 line, whereas 75% had no change in BSCVA and 6% lost 1 line. Sixteen keratoconus eyes had custom topographic neutralizing technique PRK as an alternative to penetrating keratoplasty. All eyes had improvement of astigmatism up to 5.00 diopters (D), with a mean change of 1.68 ± 1.62 D. Best spectacle-corrected visual acuity was unchanged in 8 (50%) eyes, with 4 (25%) eyes gaining 1 line, 2 (12%) eyes gaining 2 lines, and 2 (12%) eyes losing 1 line of BSCVA at 6 months.

CONCLUSIONS: Management of some highly aberrated eyes is now possible with topography-guided ablation using the WaveLight ALLEGRETTO platform and custom topographic neutralizing technique. Safety was acceptable for small optical zone and decentered ablation retreatments. The topography-guided ablation could be an alternative treatment for keratoconus patients if keratoplasty is otherwise indicated. The algorithms for custom topographic neutralizing technique need further refinement. [*J Refract Surg.* 2008;24:S439-S445.]

Topographic-guided laser ablation attempts to neutralize and preserve the aspheric shape of the cornea and has been described as a new tool for the treatment of highly aberrated eyes. The excimer laser ablation based on corneal topography is less dependent on intraocular physiologic changes and can be used to treat irregular corneas even in cases where it is not possible to obtain reproducible wavefront measurements.

Custom topographic neutralizing technique is a method developed to optimize topographic-guided treatments of aberrated eyes with the ALLEGRETTO WAVE (WaveLight AG, Erlangen, Germany). Custom topographic neutralizing technique helps adjust for the induced refractive change of surface regularization from topography-guided treatments.

Topographic-guided ablation with the WaveLight ALLEGRETTO incorporates the ALLEGRETTO WAVE Topolyzer with the T-CAT software for treatment.¹ The Topolyzer is a 20-ring topographer that uses up to 22,000 points to map the surface. As the topographer does not give any refractive data, the patient's refraction has to be adjusted based on the surface irregularity being corrected. Custom topographic neutralizing technique was developed to help improve refractive predictability and can be used to treat aberrated eyes, including enlargement of small optical zones, correction of decentered optical zones, and for the primary treatment of asymmetrical astigmatism.

The ALLEGRETTO laser incorporates the Q-value assisted treatment mode to improve the corneal aspheric profile, allowing prediction of the final corneal asphericity. Adjustment of the different ablation patterns is possible using this plat-

From the University of British Columbia and Pacific Laser Eye Centre, Vancouver, British Columbia, Canada (Lin, Holland); and the Department of Refractive Surgery, Cole Eye Institute, Cleveland Clinic, Cleveland, Ohio (Rocha, Krueger).

This study was supported by a Cleveland Clinic institutional grant from Research to Prevent Blindness Inc, New York, NY.

Drs Lin, Holland, and Rocha have no financial interest in the materials presented herein. Dr Krueger receives consulting and research funds from Alcon Laboratories Inc, Ft Worth, Tex.

Correspondence: David T.C. Lin, MD, FRCSC, 5/F, 1401 W Broadway, Vancouver, BC, Canada V6H 1H6. E-mail: tclin@shaw.ca

TABLE

Clinical Outcomes of Previously Treated LASIK Eyes With Decentered Ablation, Symptomatic Small Optical Zones, and Keratoconus Treated By Custom Topographic Neutralizing Technique

	Groups		
	Decentered Ablation	Small Optic Zone	Keratoconus
No. of treated eyes	67	48	16
Age (y)	48.38±8.57	46.67±8.19	43.75±7.01
Astigmatism			
Preoperative	-0.67±0.45	-0.54±0.16	-2.56±0.34
Postoperative	-0.33±0.43	-0.21±0.08	-0.84±0.04
Mean UCVA			
Preoperative	20/52±0.55	20/47±0.21	20/106±0.21
Postoperative	20/24±0.25	20/22±0.37	20/35±0.45
Mean BSCVA			
Preoperative	20/26±0.14	20/21±0.17	20/28±0.33
Postoperative	20/20±0.09	20/20±0.27	20/24±0.30
Mean Q value			
Preoperative	0.55±0.45	0.89±0.45	-0.64±0.30
Postoperative	0.44±0.34	0.58±0.26	-0.40±0.36

UCVA = uncorrected visual acuity, BSCVA = best spectacle-corrected visual acuity, Q-value = asphericity

form. Topography-guided ablation offers a potential treatment for symptomatic, postoperative refractive surgical retreatments, keratoconus eyes, and corneal irregularities, such as astigmatism after keratoplasty.

The purpose of this study is to evaluate the results of custom topographic neutralizing technique in aberrated eyes, including enlargement of small optical zones, decentered ablation, and keratoconus eyes using the ALLEGRETTO WAVE Excimer Laser.

PATIENTS AND METHODS

This retrospective consecutive case series comprised 131 aberrated eyes that underwent custom topographic neutralizing technique with the ALLEGRETTO WAVE. Patients were divided into three groups. Group 1 (decentered ablation group) comprised 67 eyes of 67 patients with decentered ablations from previous LASIK treatment. Group 2 (small optic zone group) included 48 eyes of 43 patients with symptomatic small optical zones after previous LASIK. Group 3 (keratoconus group) comprised 16 unoperated eyes of 10 patients with keratoconus. The study was conducted at The University of British Columbia and Pacific Laser Eye Centre, Canada. Informed consent was obtained from all patients in accordance with the Declaration of Helsinki.

Age range for the entire study population was 30 to

62 years. Mean patient age was 48.38±8.57 years in the decentered ablation group, 46.67±8.19 years in the small optic zone group, and 43.75±7.01 years in the keratoconus group. Of the 131 patients, 77 (59%) were women and 54 (41%) were men. The mean topographic astigmatism was -0.67±0.45 D preoperatively and -0.33±0.43 D at 6 months after topographic neutralizing technique ablation in the decentered ablation group, -0.54±0.16 D preoperatively and -0.21±0.08 D postoperatively in the small optic zone group, and -2.56±0.34 D preoperatively and -0.84±0.04 D postoperatively in the keratoconus group. Mean corneal asphericity (Q value) was +0.55±0.45 preoperatively and +0.44±0.34 at 6 months postoperatively in the decentered ablation group, +0.89±0.45 preoperatively and +0.58±0.26 postoperatively in the small optic zone group at 1 year, and -0.64±0.30 preoperatively and -0.40±0.36 postoperatively in the keratoconus group at 6 months (Table).

The decentered ablation group and small optic zone group underwent topography-guided LASIK retreatment by flap lift with the ALLEGRETTO WAVE. The study compared preoperative, 6-month, and 1-year results, looking specifically at the topographic central monodiotropic optical zone, best spectacle-corrected visual acuity (BSCVA), uncorrected visual acuity (UCVA), and predictability of refraction.

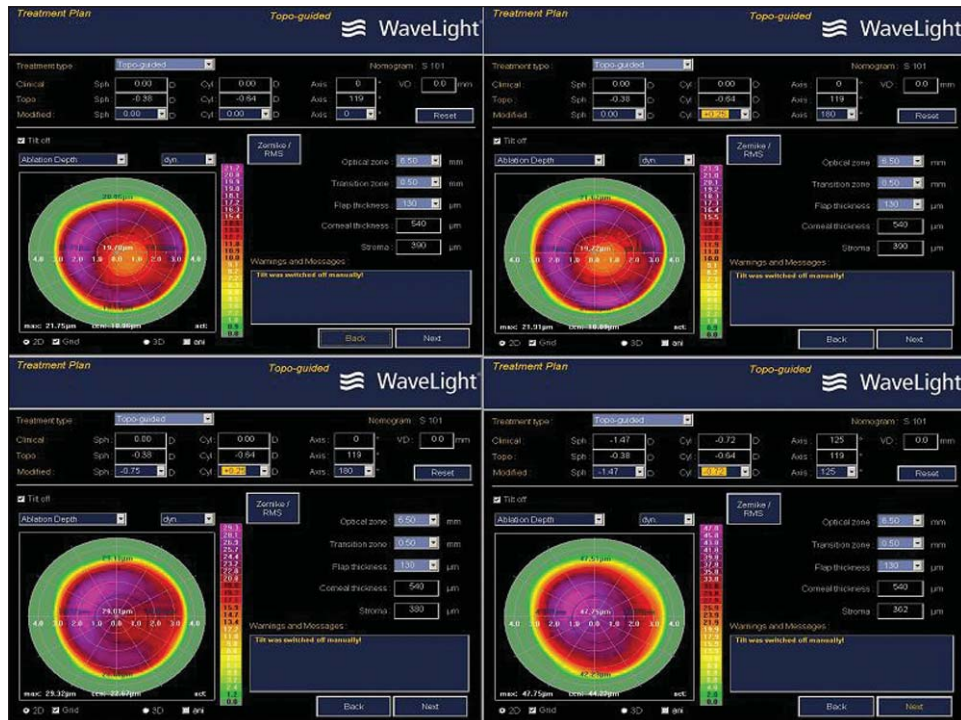


Figure 1. Plano ablation planning. The “donut” ablation pattern is a mini hyperopic treatment. Performing such a treatment on the eye induces myopia. Therefore, this effect can be “neutralized” from the topography treatment by adding more minus to the treatment. Step 1 (top left): Plano treatment (hyperopic treatment). Step 2 (top right): TNT, neutralizing cylinder (0.00 -0.25 × 90). Step 3 (bottom left): TNT, neutralizing cylinder and sphere (-0.75 +0.25 × 90). Step 4 (bottom right): Final treatment = manifest refraction (MR) + neutralized refraction (NR), MR: -1.00 -0.50 × 125, NR: -0.75 +0.25 × 180, = -1.50 -0.75 × 125, Corneal plane: -1.47 -0.72 × 125.

The keratoconus group comprised 16 keratoconus eyes that were on a corneal transplant list and had a BSCVA of 20/40 or better. All eyes were contact lens-intolerant, and residual corneal thickness was at least 300 µm of stroma. In all cases, the topography examinations were reproducible with an ALLEGRETTO Topolyzer. Mean preoperative astigmatism was 2.56 ± 0.34 D, keratometry 47.7 ± 3.22 D, and pachymetry 0.475 ± 0.60 mm.

Symptoms were evaluated by patient history before and 6 months after surgery as obtained by chart review. Symptoms were reported as blurred or hazy vision, halos and starbursts, poor night vision, image doubling, and glare.

SURGICAL TECHNIQUE

Laser ablation was performed using custom topographic neutralizing technique in all cases by two surgeons (D.L., S.H.). Custom topographic neutralizing technique planning involves four steps. Step 1 is to analyze the plano treatment produced by the T-CAT software for smoothing the cornea. The plano treatment is produced by the Topolyzer when no refractive input is entered, which, in an eye undergoing optical zone enlargement, is essentially an asymmetrical hyperopic treatment. Step 2 identifies the cylinder induced by the plano treatment and the amount of astigmatic treatment needed for neutralization. Step 3 adds a myopic treatment in the center to compensate for the initial hyperopic ablation. In step 4, the manifest refraction is added to calculate the final treatment (Fig 1).

All cases of LASIK retreatment for the decentered ablation and small optic zone groups involved lifting the flap. Using topical anesthesia (proparacaine 0.5%, Alcaine; Alcon Laboratories Inc, Ft Worth, Tex), the temporal flap edge was marked at the slit lamp with a 30-gauge needle at one spot as the flap edge is usually difficult to visualize under the laser microscope. The patient was then positioned under the laser microscope and the flap edge lifted with a Sinskey hook. A Suarez spatula was then used to lift the entire flap at the edges to the hinge. A cyclodialysis spatula was introduced at the hinge, and the flap adhesions broken away from the hinge. The flap was fully lifted and the topography-guided ablation performed. After the ablation, 70% ethanol in balanced saline solution (BSS) was applied to the stromal bed epithelial edges for 30 seconds and any previous stromal epithelial anomalies or ingrowth removed with a spatula. The flap was floated back in position with BSS and dried in position. A bandage contact lens (SofLens 66; Bausch & Lomb, Rochester, NY) was placed overnight in all cases.

Patients with keratoconus underwent transepithelial topography-guided photorefractive keratectomy (PRK) with the ALLEGRETTO Eye-Q 400-Hz excimer laser. The topographic neutralizing technique was used to improve predictability. Mitomycin C 0.02% was instilled for 15 seconds, and a bandage contact lens was in place until full re-epithelialization. Steroids were administered for 3 months, with a tapered dosing schedule. Patients were followed for up to 12 months.

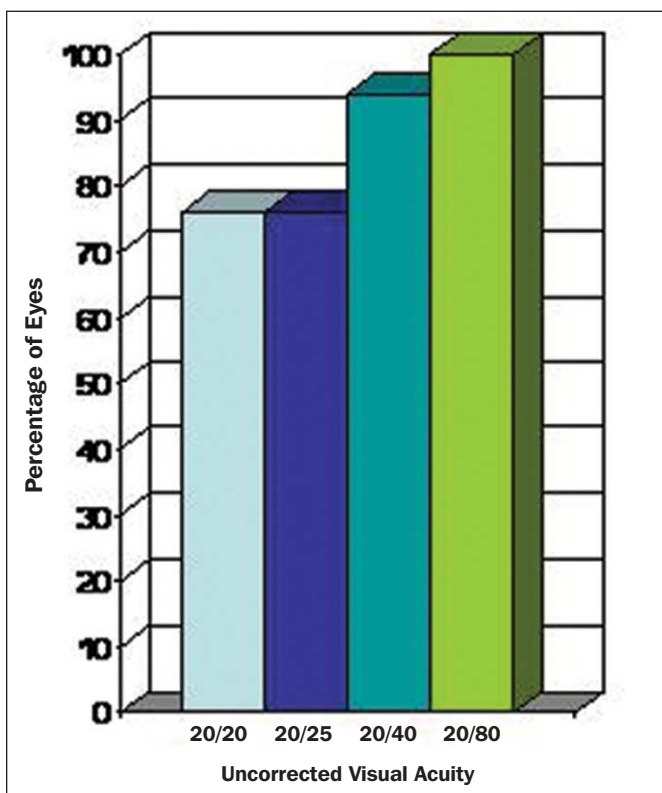


Figure 2. Uncorrected visual acuity outcomes after custom topography-guided treatment for decentered ablation. Of 67 eyes (67 patients), 76% had UCVA 20/20 or better, 76% had 20/25 or better, 94% had 20/40 or better, and 100% had 20/80 or better.

RESULTS

TOPOGRAPHY-GUIDED TREATMENT FOR DECENTERED ABLATIONS

Sixty-seven eyes with decentered ablation zones after previous LASIK underwent topography-guided LASIK. The mean ablation decentration zone was 0.92 mm preoperatively and improved to 0.3 mm postoperatively.

Postoperatively, all eyes had UCVA 20/80 or better, with 94% 20/40 or better and 76% 20/20 or better (Fig 2).

Additionally, 5% of eyes gained ≥ 2 lines of BSCVA, with 24% gaining 1 line and only 1% losing ≥ 1 line. Seventy-one percent of patients had no change in BSCVA. Predictability of refraction was good, with all eyes being within 2.00 D, 94% within 1.00 D, and 76% within 0.50 D of the attempted refractive outcome.

CUSTOM TOPOGRAPHY-GUIDED LASIK: OPTICAL ZONE ENLARGEMENTS

Forty-eight previously treated LASIK eyes with small optical zones underwent topography-guided LASIK retreatment, by first lifting the flap and then undergoing laser ablation. After laser retreatment for

optical zone enlargement, the mean topographic central monodioptric optical zone was 5.6 mm compared to 3.9 mm preoperatively (Fig 3).

Postoperatively, all eyes had UCVA of 20/80 or better, with 94% 20/40 or better, 88% 20/25 or better, and 63% 20/20 or better. Nineteen percent of eyes had an improvement in BSCVA of ≥ 1 line, whereas 75% of eyes had no change in BSCVA. Additionally, 6% of eyes lost 1 line of BSCVA. The refractive outcome was found to be predictable, with all eyes being within 2.00 D, 94% within 1.00 D, and 81% within 0.50 D of attempted.

TOPOGRAPHY-GUIDED PRK FOR KERATOCONUS

Sixteen keratoconus eyes of 10 keratoconus patients with a BSCVA of 20/40 or better who were on a corneal transplant list underwent topography-guided PRK for correction of irregular astigmatism. At the last postoperative follow-up, all eyes achieved an improvement in preoperative corneal astigmatism with 50% ≤ 1.00 D, 13% between 1.00 and < 2.00 D, 12% between 2.00 and 3.00 D, 19% between 4.00 and 5.00 D, and 6% > 5.00 D. Astigmatism improved by a mean of 1.68 ± 1.62 D. Eighty-eight percent of patients reported clear vision with no haze.

Preoperatively, all eyes had a BSCVA of at least 20/40, with 81% 20/30 or better, 56% 20/25 or better, and 38% 20/20 or better. The high numbers of bilateral treatments were because of the anisometropia induced from the monocular correction in these contact lens-intolerant patients. Although six of these second eye treatments had a BSCVA of 20/20, they all had topographic keratoconus and anisometropia. Postoperatively, all eyes had a BSCVA of at least 20/40, with 94% 20/30 or better, 94% 20/25 or better, and 31% 20/20 or better (Fig 4). Fifty percent of eyes had no change in BSCVA, whereas 25% gained 1 line, 12% gained 2 lines, and 12% lost 1 line. Overall, topographic-guided PRK with custom topographic neutralizing technique was effective in reducing corneal astigmatism and irregularity in eyes with keratoconus within the first year of treatment. Two (12%) eyes lost 1 line of BSCVA.

Clinical outcomes of all groups are summarized in the Table.

SYMPTOMS

All patients complained about either blurred or hazy vision, halos and starbursts, poor night vision, image doubling, or glare before surgery. At 6 months postoperative, a persistence of symptoms was reported by 19.5% of patients in the decentered ablation group, 18.7% in the small optic zone group, and 12.5% in the keratoconus group.

- 5 years post LASIK
- Preop : -1.00-0.50x125 10 months postop
- BSCVA : 20/20 UCVA : 20/25
- TGL Tx: -1.47-0.72x125 Rx : -0.25-0.25x090 20/20
- CMOZ: 2.6mm CMOZ: 4.6mm

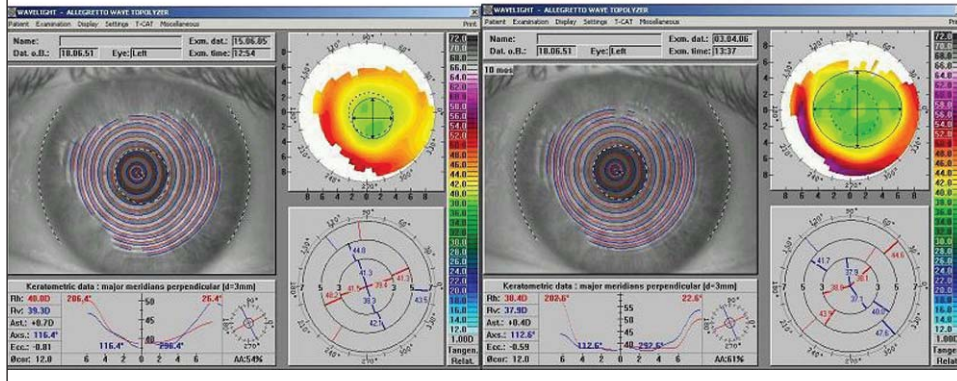


Figure 3. An example of pre- and postoperative topography for optical zone enlargement. One color change equals 1.00 D change.

DISCUSSION

Although wavefront-guided retreatment of symptomatic eyes has previously demonstrated excellent results,²⁻⁴ the correction of highly aberrated eyes remains a challenge to refractive surgery. The inability to capture reproducible centroids on wavefront maps is one of the limitations in treating eyes with highly irregular corneas.^{4,5} Topography-guided ablation does not have this limitation, and a custom topographic neutralizing technique may offer improved predictability of topography-guided LASIK and PRK. Consequently, topography-guided ablation may be a useful solution for the unhappy, symptomatic refractive surgery patient, especially among those in whom it is not possible to capture reliable wavefront maps.^{4,5}

Although topography-guided ablations have been previously investigated with various laser platforms nearly a decade ago, and prior to the rise of wavefront-guided customization,⁶⁻¹⁰ its access was never made commercially available to the average surgeon wishing to correct highly aberrated eyes. Rather wavefront-guided ablation became widely available, such that the terms “custom LASIK” and “custom PRK” are now identified with wavefront rather than topographic treatment.

The equivalency of topography-guided and wavefront-guided ablation has been previously shown with the NIDEK platform (NIDEK Co Ltd, Gamagori, Japan) in virgin eyes.¹¹ This comparison, however, has never been made among highly aberrated retreatments, and even now both wavefront- and topography-guided methods have their limitations. The greatest criticism for

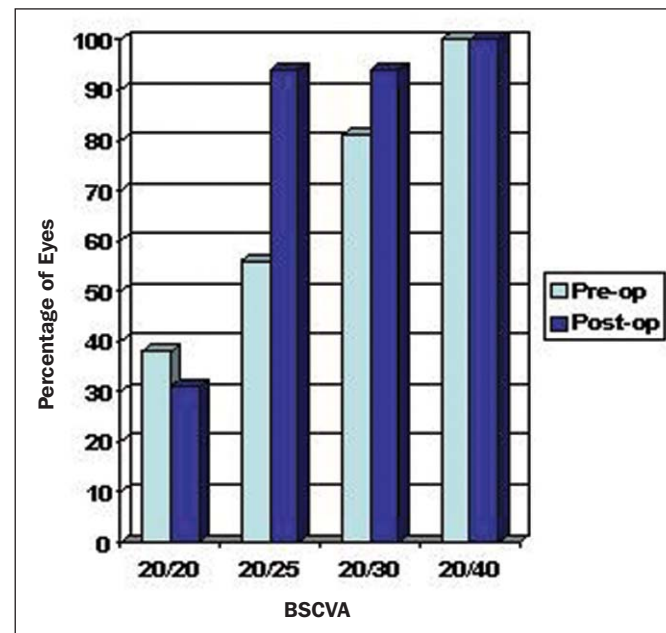


Figure 4. Best spectacle-corrected visual acuity (BSCVA) outcomes after topography-guided PRK for keratoconus. Of 16 eyes (10 patients), 38% had preoperative BSCVA \geq 20/20, which decreased to 31% postoperatively; 56% had preoperative BSCVA \geq 20/25, which increased to 94% postoperatively; 81% had preoperative BSCVA \geq 20/30, which increased to 94% postoperatively; and 100% had pre- and postoperative BSCVA \geq 20/40.

wavefront customized retreatments is the lens-induced variability with age and the fact that complex retreatments depend on these factors, rather than solely on the corneal irregularity.¹² For topographic customization, the lack of predictability of the final refractive

outcome is most criticized, although a recent resurgence in topography-guided retreatments with the WaveLight ALLEGRETTO laser and Topolyzer suggests that this limitation can be overcome.^{13,14} Previous studies in symptomatic eyes following refractive surgery have reported an improvement of BSCVA from a mean of 20/32 preoperatively to 20/21 postoperatively.¹⁴ Despite this improvement, the refractive outcome may be less predictable due to the unknown spherical component of the correction that changes the refraction postoperatively.

The custom topographic neutralizing technique method of optimizing refractive outcomes is one strategy for enhancing predictability by compensating for these refractive changes associated with topography-guided ablation. Without refractive compensation, smoothing of a previously treated myopic ablation typically induces myopia as the optical zone is enlarged. This is evident in the plano topographic treatment where no refractive input is entered. By adjusting for the amount of myopia induced with custom topographic neutralizing technique, the predictability can be improved in these cases. Similarly, smoothing a decentered ablation or asymmetrical astigmatism induces refractive astigmatism as evident in the plano topographic treatment. Using custom topographic neutralizing technique to adjust for the amount of induced astigmatism in these cases should improve predictability.

With this method, aberrated eyes such as small optical zones, decentered optical zones, and irregular astigmatic corneas may be treated with improved predictability over our previous unpublished experience with topography-guided ablations when our results were similar to those reported by others.^{13,14} In our study, we have shown the final refraction to be within 1.00 D of intended in 94% of eyes with both decentered and small optical zone retreatments, with more than 75% of these being within 0.50 D. Although these numbers could be improved with further refinement, the complexity of these cases should not be underestimated. Rather these outcomes would likely rival the best predictability of complex wavefront-guided retreatments, especially without a well accepted nomogram or strategic approach.

Although our study highlights the objective findings of improved outcome using the custom topographic neutralizing technique method, we attempted to retrospectively report the symptoms experienced by our patients before and after treatment. Following custom topographic neutralizing technique, only 18% of patients reported any visually disabling symptom in comparison to 100% prior to custom topographic neutralizing technique. Our impression was that many

patients appreciated the improved quality of vision even in situations where there was a small residual refractive error. Our results show promise for managing symptomatic patients with decentered laser ablations and small optical zones. Evidence of topographic regularization (ie, reduced zone decentration and larger central monodioptic optical zones) and even improvements in BSCVA were seen in both groups, with few eyes showing a minimal loss of 1 line of BSCVA. The fact that 76% of the decentered eyes and 63% of the small optical zone eyes could finally see 20/20 or better uncorrected further gives evidence to the relative predictability of the custom topographic neutralizing technique method.

Among the keratoconus eyes, our study demonstrated that contact lens-intolerant patients awaiting corneal transplants may have an alternative with topographically directed PRK. Twenty-five percent of cases gained 1 line of BSCVA, and improvement of astigmatism was observed in all cases. However, patients must have realistic expectations regarding the severity of the keratoconus and likelihood for keratometric progression. Despite our therapy, a corneal transplant is still a possibility. Custom topographic neutralizing technique improved predictability; however, expectations must remain realistic.

One new adjunct to topography-guided ablation of keratoconus is the sequential or simultaneous use of riboflavin/UVA induced collagen crosslinking.¹⁵ Although this combination is sequentially reported as a single case report with an excellent outcome,¹⁵ larger series and long-term follow-up of this method are needed to validate its promising implications. A long-term study comparing keratoconus eyes undergoing topography-guided ablation with and without collagen cross-linking would be valuable and would help to fully validate this technology.

The software for topography-guided ablation currently does not compensate for the refractive change induced by topographic smoothing of irregularities. With the custom topographic neutralizing technique method of optimizing outcomes, we propose that good refractive predictability can be achieved, and have demonstrated this with a UCVA of 20/20 in 63% to 76% of eyes.

Although managing the surgical parameters of these aberrated eyes is challenging, managing the expectations of these patients may be just as challenging. Patients with aberrated eyes following refractive surgery have high expectations. Although topography-guided treatments can help, it is necessary to educate patients as to the limitations of this technology and the need for future refinements.

REFERENCES

1. Holland SP, Lin DTC. Wavelight Allegretto. In: *Surgical Techniques in Ophthalmology—Refractive Surgery*. Philadelphia, Pa: Saunders Elsevier; 2008:57-67.
2. Carones F, Vigo L, Scandola E. Wavefront-guided treatment of abnormal eyes using the LADARVision platform. *J Refract Surg*. 2003;19:S703-S708.
3. Chalita MR, Xu M, Krueger RR. Alcon CustomCornea wavefront-guided retreatments after laser in situ keratomileusis. *J Refract Surg*. 2004;20:S624-S630.
4. Mrochen M, Krueger RR, Bueeler M, Seiler T. Aberration-sensing and wavefront-guided laser in situ keratomileusis: management of decentered ablation. *J Refract Surg*. 2002;18:418-429.
5. Krueger RR. Corneal topography vs ocular wavefront sensing in the retreatment of highly aberrated post surgical eyes. *J Refract Surg*. 2006;22:328-330.
6. Wiesinger-Jendritza B, Knorz MC, Hugger P, Liermann A. Laser in situ keratomileusis assisted by corneal topography. *J Cataract Refract Surg*. 1998;24:166-174.
7. Knorz MC, Jendritza B. Topographically-guided laser in situ keratomileusis to treat corneal irregularities. *Ophthalmology*. 2000;107:1138-1143.
8. Dausch D, Schroder E, Dausch S. Topography-controlled excimer laser photorefractive keratectomy. *J Refract Surg*. 2000;16:13-22.
9. Tamayo Fernandez GE, Serrano MG. Early clinical experience using custom excimer laser ablations to treat irregular astigmatism. *J Cataract Refract Surg*. 2000;26:1442-1450.
10. Alió JL, Belda JI, Osman AA, Shalaby AM. Topography-guided laser in situ keratomileusis (TOPOLINK) to correct irregular astigmatism after previous refractive surgery. *J Refract Surg*. 2003;19:516-527.
11. Vinciguerra P, Albe E, Gamesasca FI, Trazza S, Epstein D. Wavefront- versus topography-guided customized ablations with the NIDEK EC-5000 CX II in surface ablation treatment: refractive and aberrometric outcomes. *J Refract Surg*. 2007;23:S1029-S1036.
12. Amano S, Amano Y, Yamagami S, Miyai T, Miyata K, Samejima T, Oshika T. Age-related changes in corneal and ocular higher-order wavefront aberrations. *Am J Ophthalmol*. 2004;137:988-992.
13. Jankov MR II, Panagopoulou SI, Tsiklis NS, Hajitanasis GC, Aslanides M, Pallikaris G. Topography-guided treatment of irregular astigmatism with the Wavelight excimer laser. *J Refract Surg*. 2006;22:335-344.
14. Kanellopoulos AJ. Topography-guided custom retreatments in 27 symptomatic eyes. *J Refract Surg*. 2005;21:S513-S518.
15. Kanellopoulos AJ, Binder PS. Collagen cross-linking (CCL) with sequential topography-guided PRK: a temporizing alternative for keratoconus to penetrating keratoplasty. *Cornea*. 2007;26:891-895.